



TECHNICAL NOTE

Techniques for emergency tracheostomy

Fabrizio Giuseppe Bonanno *

Trauma Directorate, Department of Surgery, Chris Hani Baragwanath Hospital, Johannesburg, South Africa

Accepted 25 September 2007

Introduction

Emergency standard open tracheostomy is performed in impending or actual cardiac and respiratory-cardiac arrest. Indications are rare, but the procedure must be safe and rapidly effective.¹ Neither facilitating (but risky) neck manipulations nor electrocautery are required nor, because of the urgency to obtain airway ingress, are bilateral traction stitches applied. No intravenous line should be attempted, unless another operator is available or the patient is conscious and needs a rapid anaesthetic before a procedure. No anaesthetic is required in deep coma or cardiac arrest. In all other situations, etomidate, ketamine, remifentanyl or alfentanil immediately, followed by ketamine or remifentanyl or sufentanyl or alfentanil by continuous intravenous infusion, confer effective and safe emergency anaesthesia.

Techniques

General technique

Instruments are placed ready for use on the patient's abdomen in near-to-far order: skin blade, two swabs on small clamps, self-retaining retractor, mosquito

clamps, McIndoe scissors, size 11 blade for tracheotomy, tracheal dilator, the age-estimated size of cannula plus one cannula half a size smaller and another half a size bigger. The Gregory scale for endotracheal tube sizes is easy to remember: 2.5 Fr for premature babies, 3.5 Fr for newborns, 4.5 at 2 years of age, then an increase of 1 size for every 4 years. From the end of puberty to adulthood, the size for females increases to 8.5 Fr and for males to 9 Fr.

The procedure can be completed within 1.5–2 min by a coordinated team with an assistant setting up an intravenous infusion, administering drugs, checking the kit and also tracheostomy sizes and cuffs if anaesthesia is used. All may be completed within half a minute if no anaesthetic is needed (Table 1). Two techniques for two different scenarios are described below.

Scenario 1: two doctors, patient not in cardiac arrest

Initial dissection

If the trachea is palpable for at least 180° on the coronal plane, the surgeon grasps and lifts it with the non-operating thumb and index fingers. Skin and platysma are incised with two strokes of the knife by the operating hand. The assistant's dominant hand then grasps the trachea with thumb and ring finger, and presses with index and middle fingers onto the lateral superficial tissues to keep them divaricated, so that the operator may insert a self-retaining retractor. The assistant's free hand is meanwhile

* Correspondence address: PO BOX 108, Mondeor, Johannesburg 2110, South Africa.

E-mail address: bonannogf@hotmail.com.

Table 1 Technical tips

Oxygen is lifesaving for the hypoxaemic patient
Keep calm and remember the motivating aim of this aggressive procedure
Treat the trachea with utmost care; it is a fragile but vital structure
Stay on the midline to avoid complications
In emergency only a scalpel, mosquito clamp and cannula are essential

tamponading any bleeding in a touch-and-go fashion with a small gauze swab on a small clamp (Fig. 1). If the trachea is not palpable for at least 180°, the assistant will have to use index and middle fingers to press and keep divaricated laterally the soft-tissue planes on each side of the dissection.

Muscle plane

While the assistant is thus occupied, the operator's operating hand incises the midline raphe connecting

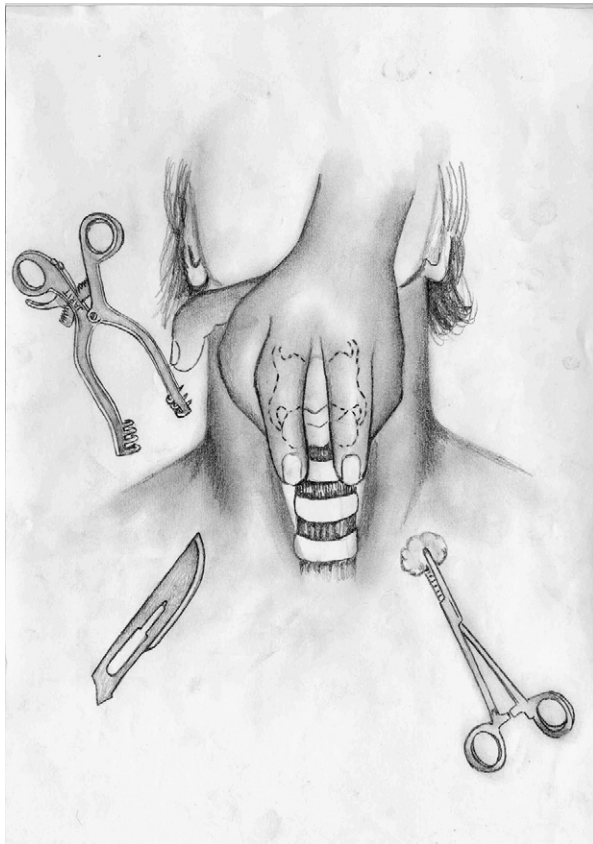


Figure 1 Position of hands during initial dissection. The operator is on the right side and holds the dissecting knife with the operating hand and a self-retaining retractor with the non-operating hand. The assistant on the left side holds and raises the trachea with the thumb and ring fingers of the operating hand, using the index and middle fingers to keep the soft tissues laterally divaricated; the non-operating hand is used for tamponading bleeding.

the sternohyoids, spreads these with a mosquito clamp and with the non-operating hand inserts a self-retaining retractor between the strap muscles.

Pretracheal space

Once the pretracheal space is displayed, the thyroid needs to be pulled upwards if it is in the middle of the dissection plane. A Langenbeck's retractor in the operator's free hand supports the mosquito clamp that is held by the operating hand to separate the trachea from the thyroid fascia. The isthmus is clasped by two mosquito clamps, first on the contralateral side and then on the ipsilateral side, and is divided in the middle with McIndoe scissors. The two stumps are tied. If the thyroid is not completely in the middle of the dissection plane, it is similarly pulled up by a Langenbeck retractor, supported by mosquito dissection of the thyroid fascia by the operating hand, until the cricoid cartilage and tracheal rings are specifically identified.

Tracheotomy

If the trachea is deeply sited, the assistant lifts it upwards with bilateral hooks. A size 11 blade is used to incise vertically the membrane between the

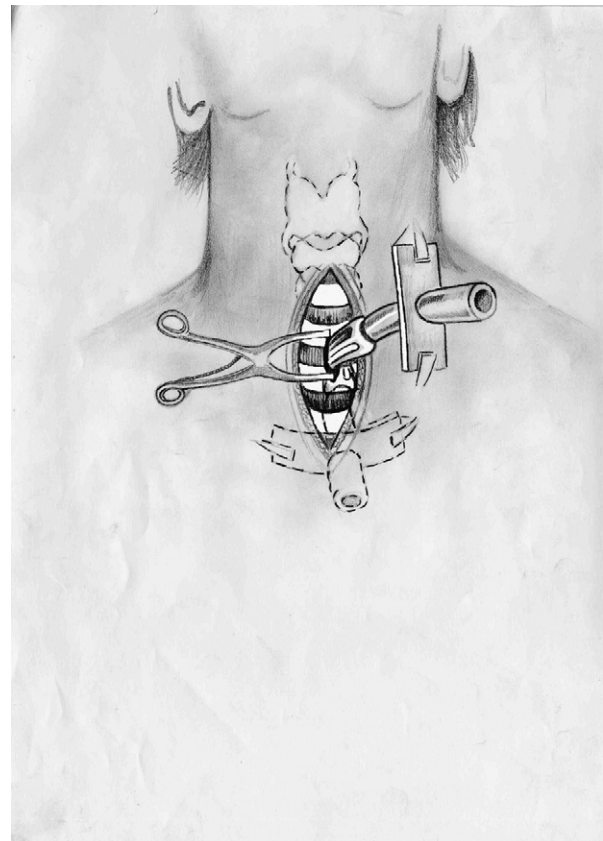


Figure 2 The tracheostomy cannula is first inserted perpendicular to the trachea; once engaged inside, it is twisted by 90° to the desired position.

second and third tracheal rings and to make a slit 2–3 mm long in the superior and inferior adjacent cartilaginous ring borders.

Tracheostomy

A mosquito clamp in the operator's non-operating hand is used to enlarge the tracheotomy, first vertically and then slightly and gently horizontally. The clamp is then exchanged for a tracheal dilator to accommodate the tracheal cannula inserted by the operating hand, while the ostomy is held divaricated on the vertical, more inelastic, axis, to avoid both cuff damage against the cartilaginous rings and overstretching the ostomy in its weak horizontal axis. The selected cannula is inserted perpendicular to the tracheal axis from lateral, and is then turned 90° to lie inside and parallel with the trachea (Fig. 2). The cannula is immediately attached via an adaptor to a manually ventilated resuscitator bag with a transparent face mask, positive end-expiratory pressure valve and reservoir bag of 100% oxygen. The cuff is inflated at an appropriate pressure and, after a brief manual ventilation check for bilateral chest excursion and the presence of bilateral breathe sounds, the tracheostomy is connected to a ventilator.

Scenario 2: one doctor only or patient in cardiac arrest

Dissection

The operator incises the tissues with repeated strokes of the knife plane by plane, strictly in the midline, until the trachea is seen. The index finger of the non-operating hand used as a trephine assists in the dissection and estimates tracheal depth.

Tracheotomy

If the thyroid is in the middle of the dissection plane, it is retracted with a Langenbeck's retractor or by the index and middle fingers of the free hand, also keeping apart the soft tissues, which are dissected with curved McIndoe scissors away from the tracheal fascia and then divided in the midline. There should be no attempt to identify the cricoid cartilage or specific cartilaginous rings. The ostomy is made approximately 2–3 cm from the estimated cricoid cartilage level. However, if the cricoid and the cartilaginous rings are easily and immediately identified, a size 11 blade is used to incise vertically the membrane between the second and third tracheal rings and to make a slit 2–3 mm long in the superior and inferior adjacent cartilaginous ring borders. Haemostasis at the thyroid isthmus stumps is assured later, after access to oxygen is obtained.

Tracheostomy

A mosquito clamp is now used to enlarge the tracheotomy, first vertically and then slightly and gently horizontally, and finally vertically. This facilitates insertion of the tracheal cannula by the operating hand, perpendicular to the tracheal axis from lateral. The cannula is then turned 90° to lie inside and parallel with the trachea, and is immediately attached via an adaptor to a manually ventilated resuscitator bag with a transparent face mask, positive end-expiratory pressure valve and reservoir bag of 100% oxygen. The cuff is inflated at an appropriate pressure and, after a brief manual ventilation check for bilateral chest excursion and the presence of bilateral breathe sounds, the tracheostomy is connected to a ventilator. If the patient is having external cardiac massage, the trachea, cannula and adaptor have to be stabilised with the fingers of the free hand, to avoid dislodgement by back-pressure of air.

Unexpected problems

Occasionally the trachea is too small for the pre-estimated available cannulae. This is a distressing situation and a real-life temporary drama, in which the operator can easily damage the trachea in the attempt to force an opening. Therefore, a set of three cannulae should be prepared, of the estimated size, half a size smaller and half a size bigger. If, however, the trachea is too big for the available cannulae, the largest available size should be inserted and oxygenation started. The cannula can be exchanged for a more suitable size once the patient is stabilised.

A goitre extending to the jugular fossa or further should be pre-appraised by inspection or palpation. The recommended approach is to extend the incision vertically upwards by another 2 cm and to enter the space between pretracheal and thyroid fasciae from above with the index finger and McIndoe scissors. The two fasciae are then separated until the interspace between second and third cartilaginous rings is identified. If fascial adhesions prevent entry into the interfascial plane of dissection, the safest approach is not to force with scissors and risk damaging the trachea, but to cut the goitre in its upper portion longitudinally with the knife until the open scissors are seen or felt. The tracheotomy may then proceed through the remaining thyroid tissue at 2–3 cm from the estimated cricoid cartilage level. Diathermy and stitches will be required after airway access, to deal with the bleeding thyroid. Another option is to use percutaneous transtracheal ventilation for temporary oxygen ingress via an available tracheal space or through the cricothyroid membrane.² An assistant holds this in place while the

operator continues with the thyroidotomy, until a tracheotomy can be safely carried out.

Acknowledgements

I thank Dr. Andy Barnett and sisters Zandi and Queenie of the CHBH Trauma Unit for assistance. Justice Phukubje (justicephukubje@yahoo.co.uk) has done the illustrations.

References

1. Bonanno FG. An appraisal on emergency tracheostomy. *Injury Extra* 2007;38:346–9.
2. Divatia JV, Bhadra N, Kulkarni AP, Uphadhye SM. Failed intubation managed with subcricoid transtracheal jet ventilation followed by percutaneous tracheostomy. *Anesthesiology* 2002;96:1519–20.